# Complex Spinal AVM: Curative Endovascular Treatment Supported by 4D Angiography Imaging

Courtesy: Saruhan Cekirge, MD, and Isil Saatci, MD, Department of Interventional Neuroradiology, Koru Hospital, Ankara, Turkey

## Patient history

A 27-year-old female presented with progressive weakness. A large spinal arteriovenous malformation (AVM) was diagnosed affecting both legs located in the conus medullaris and cauda equina. Since the patient's clinical condition was worsening rapidly, a decision was made to perform curative AVM treatment.

## Diagnosis

Complex spinal AVM

Saruhan Cekirge, MD

## Treatment

The spinal AVM was fed by left L1 and L2 radiculomedullary contribution via the posterior and anterior spinal artery. A spinal 4D angiography run was used to assess the AVM nidus and feeder orientation. In just a few minutes, it was possible to visualize the whole morphology in order to find the ideal working projection to guide the microcatheter into the right position, i.e. the nidus of the AVM. A prolonged intranidal ONYX® injection was administered to completely close the AVM.

The patient recovered progressively from her symptoms and was able to walk again without assistance.

## Comments

Following on from DSA, 3D angiography, and flat panel CT, we firmly believe that 4D angiography is the next key revolution in the history of angiography. It has exactly the same decisive impact on AVM treatment as 3D angiography had on aneurysm treatment. It enables a very quick and efficient visualization of the disease morphology so that we can treat lesions much more effectively.

1a

1b

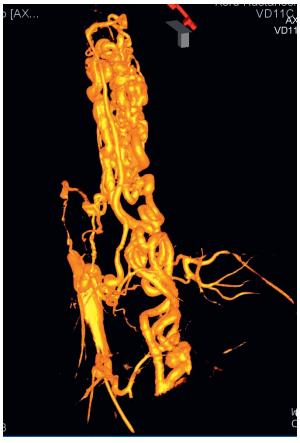

1c

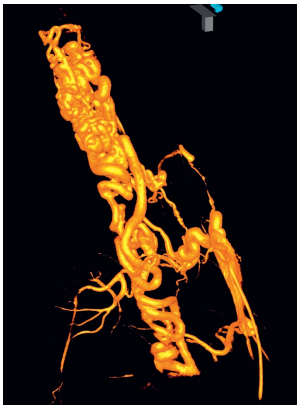

1 *syngo* Dyna4D of the spinal AVM was used to find the correct working projection.

2 Optimal working projection to see that the anterior spinal artery does not occlude during glueing (left: AP, right: lateral).

3a Anterior spinal artery with a contrast media filling from caudocranial.

3b Post op, the image shows an occluded AVM and a none occluded anterior spinal artery which is still filling with contrast media.

3c Intranidal ONYX cast after embolizational closure of the entire spinal AVM with no complications.

2

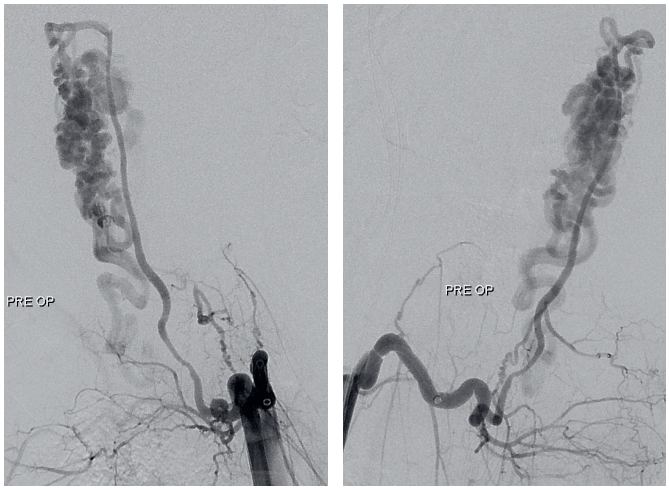


2

3a

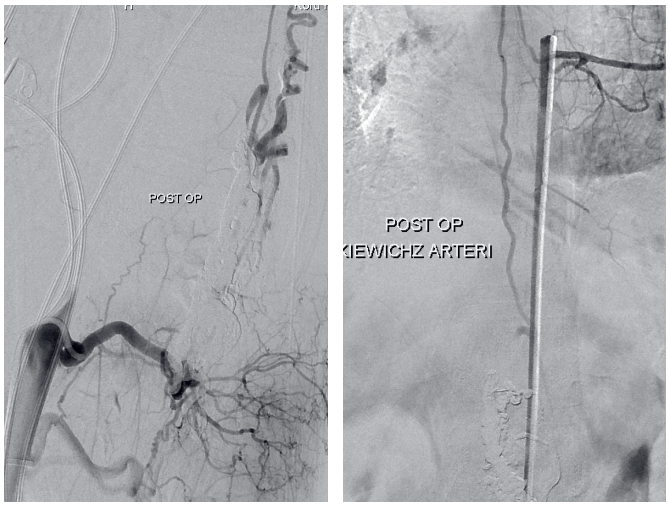


3a

3b

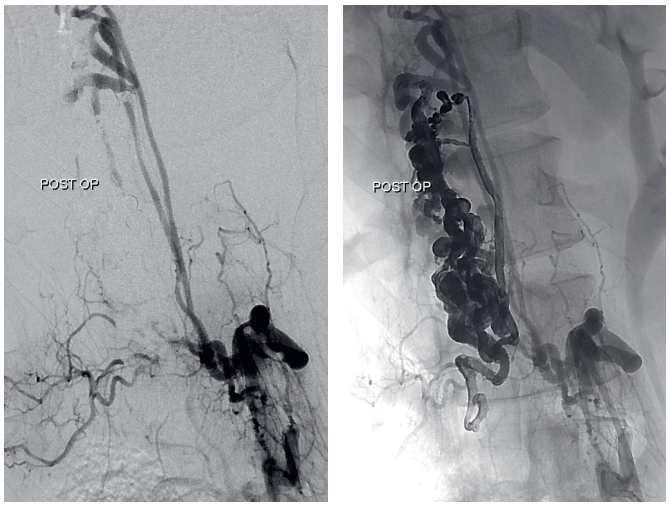


3c

## Protocol

| Acquisition protocol | 6s Dyna4D |
|---|---|
| **Injection protocol** | |
| Catheter position | Lumber artery |
| Contrast medium (CM) | 300 mg Iodine/mL |
| Test bolus | Null |
| Dilution | No |
| Injection volume | 18 mL |
| Injection rate | 3 mL/s |
| Duration of injection | 6 s |
| X-ray delay | 0 |
| Power injector used | Yes |
| **Reconstruction** | |
| Name | Dyna4D arterial sub 4D |
| VOI size | Full |
| Slice matrix | 512 x 512 |
| Kernel type | EE |
| Image characteristics | Auto |
| Reconstruction mode | Sub |
| Viewing preset | Dyna4D |

The outcomes by Siemens' customers described herein are based on results that were achieved in the customer's unique setting. Since there is no "typical" hospital and many variables exist (e.g., hospital size, case mix, level of IT adoption) there can be no guarantee that other customers will achieve the same results.

**Contact**
Stephanie Hench
stephanie.hench@siemens-healthineers.com
Cigdem Kahraman
cigdem.kahraman@siemens-healthineers.com