

A Hybrid Approach – Minimally Invasive, Image-guided Surgery in Asia

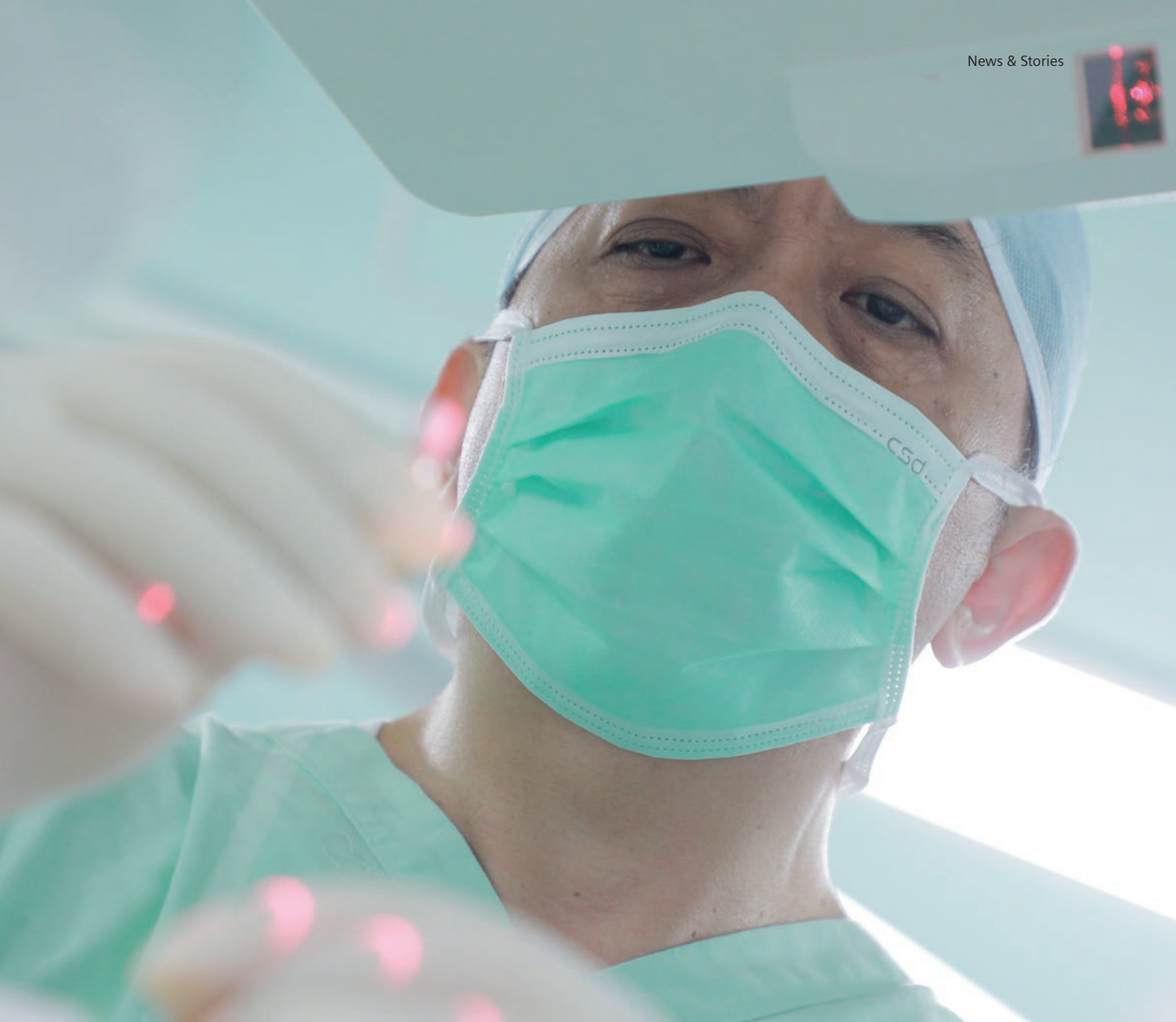
With the rich past of a former capital of commerce and power, the Taiwanese city of Tainan has many claims to fame. Its latest is the trailblazing work in minimally invasive, image-guided surgery.

Photos: Chia-Min Chang

The metropolitan area around Tainan has a population of three million who demand state-of-the-art medical treatment. Hospitals in Taiwan experience fierce competition for patients which can only be won with the latest treatment methods and technology. Robotic surgical systems and hybrid operating rooms are integral to modern Taiwanese healthcare. X-ray imaging capability in operating theaters is a must to provide minimally invasive therapy options.

Chi Mei Medical Center in Tainan, Taiwan, just celebrated its 50th jubilee. The hospital has grown with the city and now accommodates 2,450 beds. After installation of the first surgical tele-manipulator in Southern Taiwan, Chi Mei Medical Center reached another milestone with the commissioning of a new hybrid operating room equipped with a robotic imaging system. The hybrid operating room in Chi Mei is available to clinicians from many disciplines and is a critical stop for many patients along their care path. Thoracic surgery is just one example of the many procedures performed here, but it is an important one in Taiwan.





Lung cancer screening and thoracic surgery

Along with Taiwan's economic success came the inevitable air pollution. Furthermore, Taiwanese people love to cook, but often in poorly ventilated spaces directly exposed to greasy aerosols. Regardless of where the blame lies, here or in as-yet undiscovered hereditary factors, a long-term observational study has revealed that Taiwanese non-smokers are more likely to suffer from lung cancer than smokers in Europe and the U.S. [1–5]

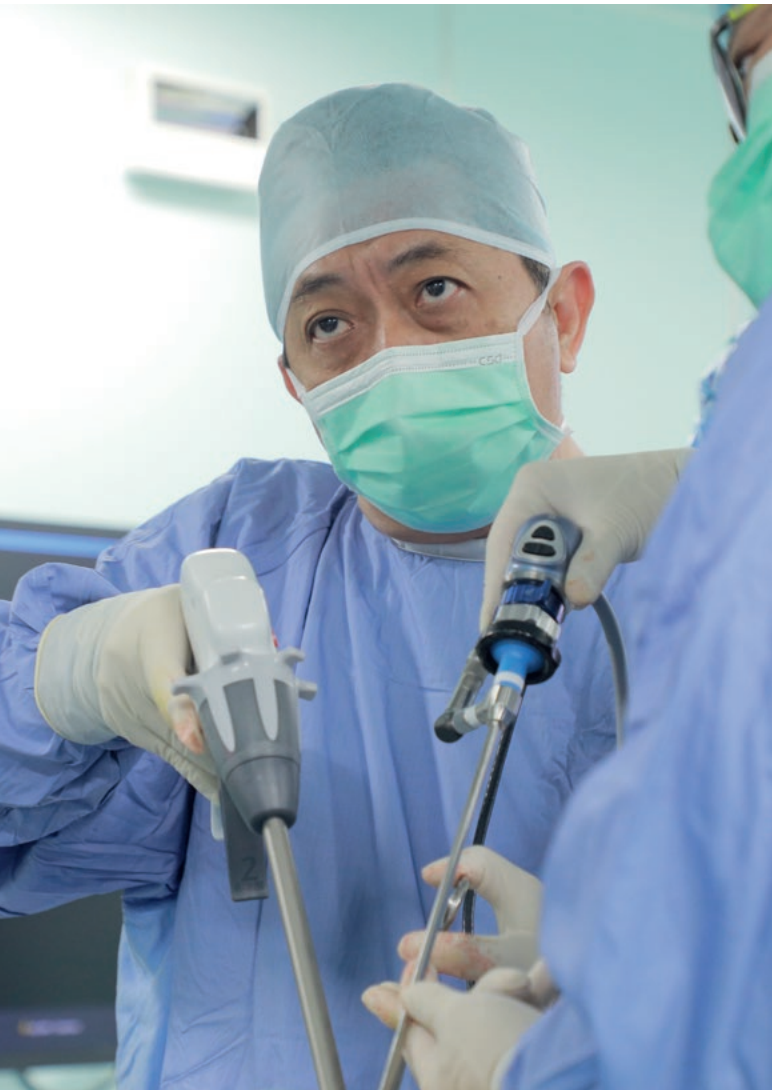In light of these puzzling statistics, as well as the recent lung cancer death of Ko Chun-hsiung, a popular movie star turned politician, health officials called for a nationwide screening trial via low-dose CT scans. With widespread screening, of course, there is then the issue of how to deal with the results. Screening can sometimes reveal several smaller lung nodules in otherwise healthy patients. To tackle this pernicious killer, Yao Fong, Head of Thoracic Surgery, and his colleagues turned to the advanced imaging capabilities of a multidisciplinary robotic imaging system. Fong has been a surgeon for almost 30 years and is the first certified attending physician in thoracic surgery in the Tainan area.

"In the last two or three years, whether due to advances in diagnostics or surgical technology, the local five-year survival rate of lung cancer has jumped to over 90% now from just above 60% in the past, which is a very important advance for us," says Fong. "Of course, a main driver of such progress is the increasing awareness among people of their health. But also, the advances in diagnostic equipment and image-guided surgery."

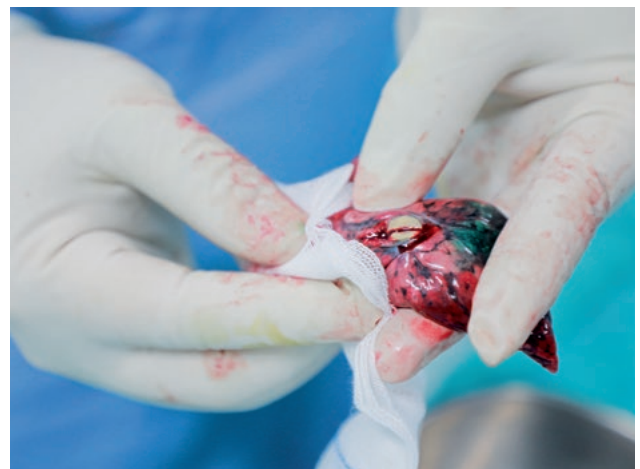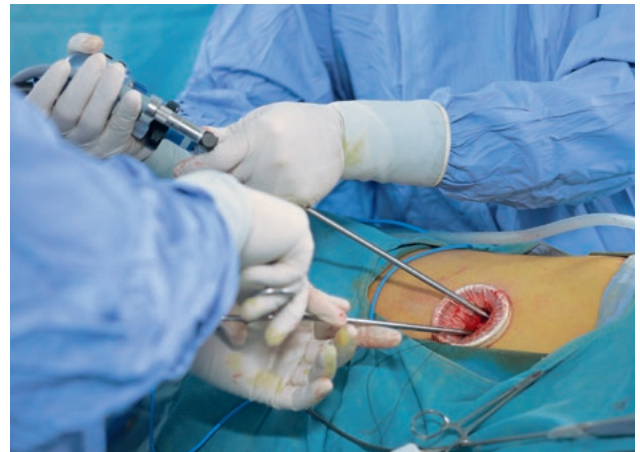Fong continues: "With the new imaging system, we can start and complete the surgery in the OR safely. These procedures are risky and have a high mortality rate, but now, I believe, our surgeons can successfully overcome the difficulties with more confidence and more assurance."*

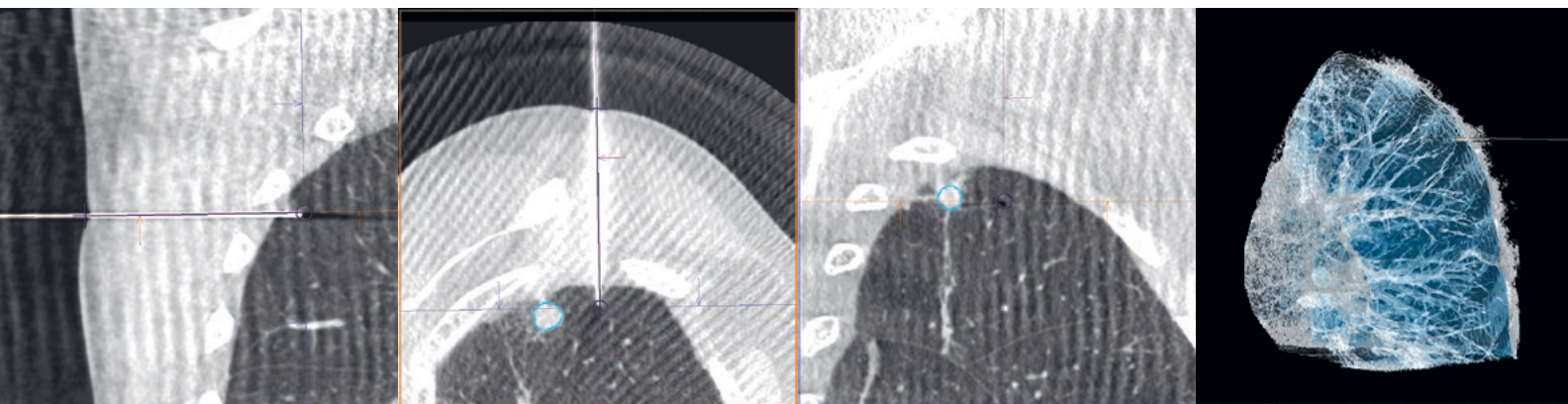
Procedural risk in treating small pulmonary nodules

Lung cancer is not simply a common disease in Taiwan, it is the leading cause of cancer death. "We treat approximately 300 lung cancer cases each year," Fong says. However, the logistical challenges in the past meant increased risks from moving patients: "Scans and tumor marking were performed in the radiology department, where we can't monitor vital signals." Fong explained that patients were given only local anesthesia until they were transferred to a regular OR for the resection of the tumor. "Transport and repositioning of the patient can cause pneumothorax, hemothorax, as well as simply discomfort and anxiety," he adds. Patients also tended to move during the transfer which



Being able to locate small, deep and thus not-palpable lesions precisely during a surgical intervention is a quantum leap in the treatment of lung cancer





Defining a needle path to the lesion in different cross-sections with syngo Needle Guidance

could cause dislocation of the marker. To make up for the loss of accuracy through dislocation, Fong says that physicians had to search manually for nodules, inserting their fingers into the incision and palpating the nodule.

Then came ARTIS pheno, and with it the ability to localize nodules during the intervention without moving the patient. The live imaging brought several advantages: Now, to remove smaller nodules, surgeons at Chi Mei mark the location with dye or solid markers and resect it in the same, safe OR environment. Before, when the procedure was split over two rooms, “marker dyes could fade or smudge,” says Yu-Feng Tian, Vice President of Chi Mei Medical Center. “We always needed to rush.” And rushing could involve more risk.

Operational efficiency is key for hospitals

Risk is not the only consideration from an administrative perspective. Healthcare is sometimes a balance between optimal clinical outcomes and cost efficiency. “ARTIS pheno has a much larger C-arm width, providing more freedom and space at the side for patient positioning,” says Fong. “We don’t have to rely on the localization procedure performed by our radiology department, and we can localize multiple lesions inside the OR. This reduces the costs of transporting patients and moving them between different departments, which is beneficial to the hospital,”* explains Tian. “This is highly advanced imaging equipment.

It helps our surgeons to perform very precise localization of some very small lesions in the OR. There is no doubt that such exact localization can facilitate surgery and reduce the overall procedure and anesthetic time,”* he adds. “With this new system, we can see small lesions in the OR in 3D,”* Fong adds.

Hospital acquired infections and surgical environments

Infection control is a global challenge in sensitive environments like the OR. According to the World Health Organization, the annual financial losses due to healthcare-associated infections are significant: “They are estimated at approximately € 7 billion in Europe, including direct costs only and reflecting 16 million extra days of hospital stay, and at about US\$ 6.5 billion in the USA.”[1] In a world with rising antibiotic-resistant infections, Chi Mei Medical Center wanted to provide that latest standards to their patients with regards to infection control.

“Since surgery time is reduced, the anesthetic time is shortened too, and this naturally facilitates the control and prevention of infection to a certain extent,” Fong says, describing the connection between surgery time and infection risk. He adds that “the new technology has fewer tubes going outside, so it has a kind of all-in-one structural design. Therefore, it helps to improve the overall cleanliness inside the room. Its microbe-proof performance is much better than the previous generation.”*

"I think that such advanced technology, allows us to expand its usage to further fields so we can offer more and better options for our patients."




Yao Fong, MD
Director of Thoracic Surgery,
Chi Mei Medical Center, Tainan, Taiwan

Impact on the patient experience

As seen with other procedures such as TAVI and EVAR**, the boundaries between disciplines are disappearing. The modern surgeon is aware of classical surgery as well as of interventional techniques including imaging. Disciplines work closer together in the hybrid OR where teamwork is important to achieve optimal outcomes. With hybrid ORs, hospitals can now provide procedures that were previously perhaps more invasive or required several different steps. When procedures can be performed with greater speed and safety in one OR, this is not only an advantage in terms of efficiency but also beneficial for the patient.

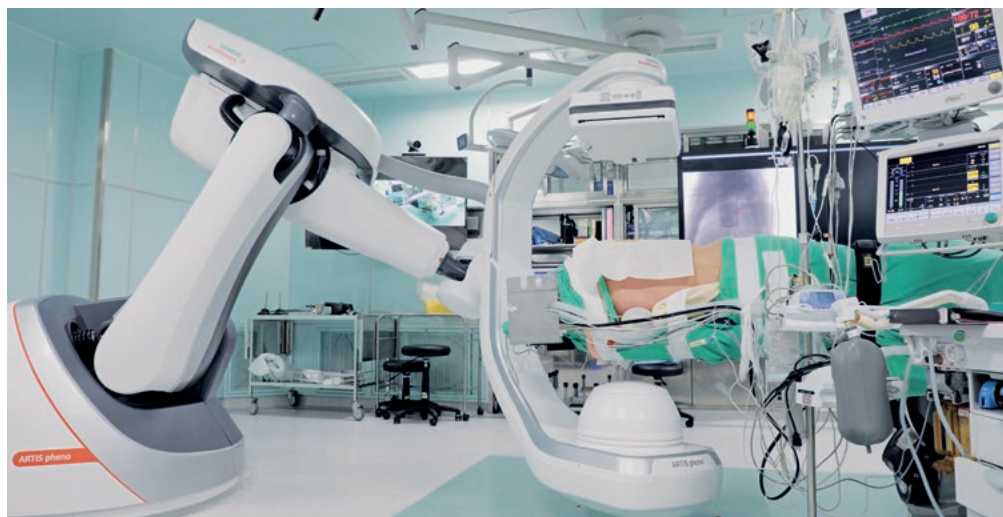"With our new system," explains Fong, "a major benefit is that we can get the patient prepared in time and with only one step: Puncture and then perform the surgery right away. Within about 30 minutes, we can make the incision. We can anesthetize the patient in advance, which can reduce panic and anxiety and, consequently, risk. So, once the tumor has been marked, we can perform the surgery promptly without any lesion localization problems, such as spread-out or fan-out of the dye. The new system has, in fact, improved our medical performance and is also helpful in terms of the accuracy of our diagnoses and treatments. For the patient, such procedures are truly minimally invasive.**"



"Risk is not what you can see, but what you cannot visualize."

Professor Chin-Hong Chang,
Director of Neurosurgery,
Chi Mei Medical Center, Tainan, Taiwan

Hybrid OR with ARTIS pheno
for thoracic surgery
and multidisciplinary use at
Chi Mei Medical Center



New therapeutic approaches

“With such an advanced system in the operating room we can be much safer.* Since we installed the new system, we have been able to improve our therapies and develop new approaches. For intraoperative image guidance, we think, that ARTIS pheno is probably the best choice,” summarizes Fong. What is best for patients goes beyond improved clinical outcomes; it’s also about safety, comfort, and reassurance. The future is all about reducing risk, whether through prevention, screening, or the support of advanced imaging to provide life-saving levels of detail. As Chin-Hong Chang, Director of Neurosurgery at Chi Mei Medical Center, explains: “Risk is not what you can see, but what you cannot visualize.” ●

* The statements by Siemens Healthineers customers described herein are based on results that were achieved in the customer’s unique setting. Since there is no “typical” hospital and many variables exist (e.g., hospital size, case mix, level of IT adoption) there can be no guarantee that other customers will achieve the same results.

** TAVI: Transcatheter aortic valve implantation;
EVAR: Endovascular aortic replacement

References

- [1] Yang PC et al., “LDCT Screening in Non-smokers in Taiwan”, U.S. National Library of Medicine, Clinical trials database, 2017. [Internet]. ClinicalTrials.gov Identifier: NCT02611570. [cited August 1, 2017]. Available from: <https://clinicaltrials.gov/ct2/show/NCT02611570>
- [2] Fulco, M, Higher than Usual Lung Cancer Incidence in Taiwanese Non-smokers, Taiwan Business TOPICS, 2018. [Internet]. [cited March 14, 2018]. Available from: <https://topics.amcham.com.tw/2018/03/higher-usual-lung-cancer-incidence-taiwanese-non-smokers/>

- [3] Taiwan Health and Welfare Report 2016, Ministry of Health and Welfare, R.O.C. (Taiwan), ISSN-24092630. Available from: <https://www.mohw.gov.tw/cp-137-521-2.html>
- [4] Taiwan Tobacco Control Annual Report 2016. [Internet]. [cited May 23, 2016]. Available from: <https://www.hpa.gov.tw/EngPages/Detail.aspx?nodeid=1069&pid=6140>
- [5] Wong MCS et al. Incidence and mortality of lung cancer: global trends and association with socioeconomic status. *Nature. Scientific Reports* 7, Article number: 14300. [Internet]. [cited October 30, 2017]. Available from: <https://www.nature.com/articles/s41598-017-14513-7>
- [6] WHO Health care-associated infections fact sheet. [Internet]. [Date accessed: May 27, 2019]. Available from: https://www.who.int/gpsc/country_work/gpsc_ccisc_fact_sheet_en.pdf

Further reading

- 1 Chao et al., “A comparison of efficacy and safety of preoperative versus intraoperative computed tomography-guided thoracoscopic lung resection” *J Thor Cardiovasc Surg*, 2018
- 2 Kostrzewa, Roessner et al., “Computed Tomography-Assisted Thoracoscopic Surgery, A Novel, Innovative Approach in Patients With Deep Intrapulmonary Lesions of Unknown Malignant Status” *Investig Radiol*, 2017
- 3 Ng et al., “Image-guided localization of small lung nodules in video-assisted thoracic surgery” *J Thorac Dis*, 2016
- 4 Chao et al., “Learning curve of image-guided video-assisted thoracoscopic surgery for small pulmonary nodules: A prospective analysis of 30 initial patients” *J Thorac Cardiovasc Surg*, 2018
- 5 Chen et al., “Image-guided thoracoscopic surgery with dye localization in a hybrid operating room” *J Thorac Dis*, 2016
- 6 Bueno et al., “Image-guided Video Assisted Thoracoscopic Surgery (iVATS) - Phase I-II Clinical Trial” *J Surg Onco*, 2015
- 7 Ng et al., “Hybrid DynaCT Scan-Guided Localization Single-Port Lobectomy” *Chest*, 2015